

# MIS Hip Joint Replacement

## Surgical Technique

**Direct Anterior** Approach



Includes  
**Enhanced  
Digital Content**

# MIS Hip Joint Replacement

## Surgical Technique

### **Direct Anterior** Approach

---

It is Stryker's mission to deliver state of the art MIS technologies and implants for hip and knee arthroplasty, while providing the highest standards of training and education for the medical community. Stryker's ultimate goal is to promote patient lifestyle recovery supported by responsible science. Stryker will endeavor to invent, develop and deliver procedural simplification through innovative technologies that provide greater patient satisfaction and potentially lead to long-term clinical success.

Minimally invasive procedures are those that offer a synergistic combination of implant and technique with the potential to improve the surgical experience of patient and surgeon.

---

#### **Scientific Advice**

Michael Nogler, M.D.  
Martin Krismer, M.D.  
Medical University Innsbruck,  
Department of Orthopaedics  
Anichstraße 35, A-6020 Innsbruck,  
Austria







William J. Hozack, M.D.  
Rothman Institute  
925 Chestnut Street  
Philadelphia, PA 19107-4216, USA

---

The decision to perform an MIS procedure is ultimately left to the surgeon's professional medical and clinical judgment. It is the surgeon who must carefully evaluate each patient to determine if MIS surgery is indeed appropriate. In some cases, the clinical risks that apply to MIS total joint arthroplasty may be greater than conventional total joint arthroplasty. Stryker strongly recommends that surgeons complete a formalized training program before attempting these operative techniques on their own.

## Table of Contents

---

	<b>Stryker Direct Anterior MIS Technique Introduction</b>	<b>1</b>
	<b>Preoperative Planning and Patient Positioning</b>	<b>2</b>
	<b>Patient Positioning</b>	<b>3</b>
	<b>The Portal</b>	<b>4</b>
	<b>Exposure of the Joint</b>	<b>5</b>
	<b>Preparation of the Capsule</b>	<b>10</b>
	<b>In Situ Osteotomy and Removal of the Femoral Head</b>	<b>11</b>
	<b>Acetabular Exposure</b>	<b>13</b>
	<b>Preparation of the Acetabulum</b>	<b>14</b>
	<b>Cup Impaction</b>	<b>16</b>
	<b>Preparation of the Dorsolateral Capsule</b>	<b>18</b>
	<b>Figure 4 Position to Mark Femoral Orientation</b>	<b>19</b>
	<b>Exposure of the Femur</b>	<b>20</b>
	<b>Opening of the Femoral Canal</b>	<b>23</b>
	<b>Rasping the Femur</b>	<b>24</b>
	<b>Implantation and Closure</b>	<b>26</b>
	<b>Stryker MIS Instrumentation</b>	<b>27</b>

Click on this image in  
your OpTech Live  
App to view videos  
on your iPad, or use  
a QR Scanner on  
your Smartphone.



## Direct Anterior MIS Technique

The Direct Anterior Approach can be used to implant a standard total hip prosthesis using instruments specially designed for minimally invasive surgery (MIS).

A modified Smith-Peterson anterior technique allows direct, unimpeded access to the hip capsule through a single incision. The approach is made through an intermuscular and internervous plane that spares tissue and leaves the gluteal muscles attached to the ilium.

- The capsule may be retained via a capsulotomy using an H-shaped incision or it may be excised
- The femoral neck is osteotomized by two sequential cuts
- After the bony disc has been removed, the femoral head can be removed without significant soft tissue distraction
- Mobilization of the capsule from the femur and placement of specially designed retractors to elevate the femur out of the wound permit direct access to the femoral canal

This Direct Anterior Surgical Technique was derived from the Stryker Interactive Training Program. Within this program are interactive MIS Hip and Knee surgical techniques that allow you to work and become familiar with Stryker's latest MIS instruments while applying them to computer-animated soft tissue and bone models.

This educational tool is one phase in a comprehensive MIS training program and is designed to help reduce the learning curve associated with MIS procedures.

To access the Stryker Interactive Training Program, use the link <http://learn.healthstream.com/strykerortho/>

You can find out more about our MIS training program by accessing our website at [www.stryker.com](http://www.stryker.com)

Please note that this MIS Surgical Technique illustrates the Accolade TMZF femoral component and the Trident acetabular component as an example. The surgical techniques presented here can be adapted to work with many Stryker Orthopaedics primary femoral and acetabular components. For details specific for the components you choose, please consult the appropriate surgical protocols.

## Preoperative Planning & Patient Positioning

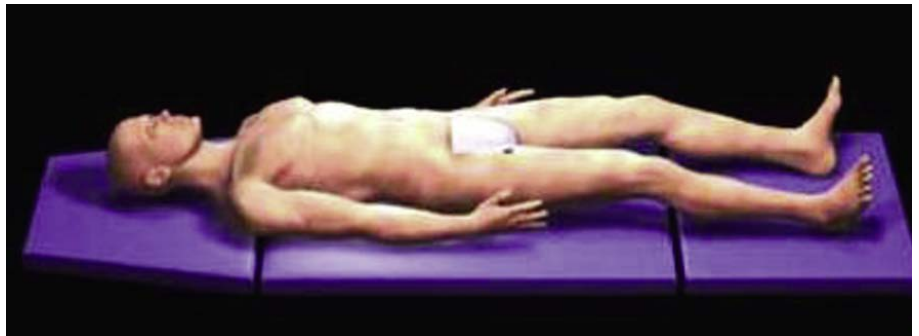Preoperative planning aids in the selection of the appropriate implant style and size for the patient's hip pathology. Preoperative X-ray analysis can be used to evaluate:

- Optimal femoral stem fit
- Prosthetic neck length
- Neck offset
- Acetabular component sizing
- Correct location of the osteotomy

Determination of probable implant style and size can facilitate operating room preparation by ensuring that the appropriate size selection is available. Anatomic anomalies that could prevent the intra-operative achievement of the established preoperative goals may also be detected through such planning.

Place the patient in a supine position on the operating table to create a predictable and stable position. A hip bump can be used to push the hip forward, but it is not required.

When preparing the femoral canal, the patient will need to be repositioned with the operative leg placed in external rotation, adduction, and extension.



## Patient Positioning

Place the patient in the supine position at the operating table. A table attachment opposite to the operated side (such as an armboard) allows for easier hyper abduction of the opposite leg during femoral exposure. Both legs are draped flexibly (only the operative leg needs to be sterilely draped, but sterile draping of both legs may be helpful for the surgical exposure). (Fig. 1)

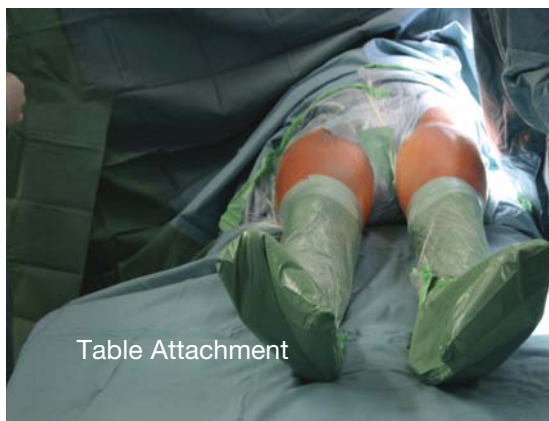

Figure 1

Palpate the anterior superior iliac spine and the greater trochanter. The proximal starting point is found two finger breadths (~ 3 cm) lateral and two finger breadths distal to the ASIS. Keep the initial incision small (6-7 cm) and extend it as needed. For increased acetabular exposure lengthen distally and for the femur proximally. Observe that the location of the incision is significantly more lateral than the original Smith-Petersen interval. See anatomic dissection on the next page. (Fig. 2a)

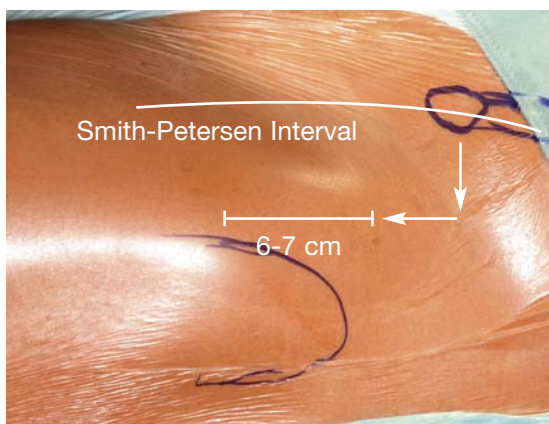


Figure 2a



Another technique to find the incision location is to draw a line between the ASIS and the GT. The proximal extent of the incision starts on this line about half way between the two landmarks. The incision should angulate gradually toward the GT rather than going straight distal. (Fig. 2b)

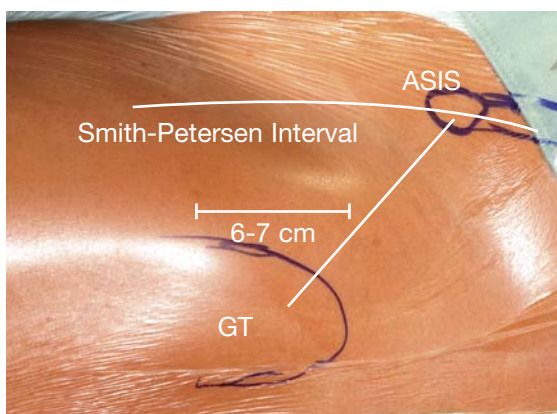
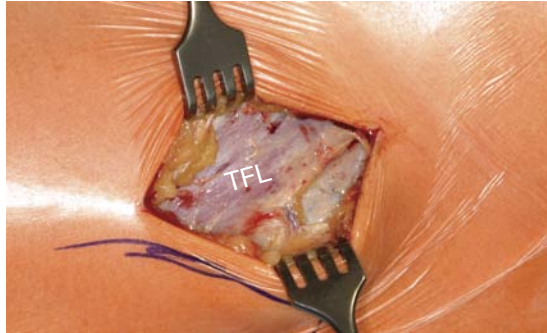


Figure 2b

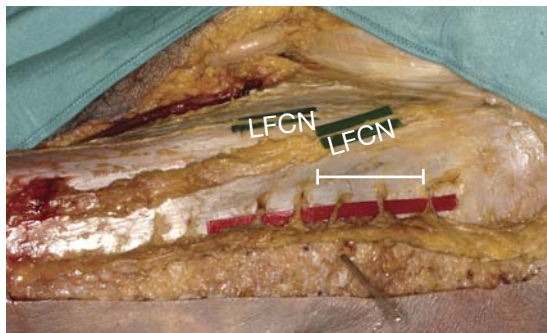


## The Portal

The lateral femoral cutaneous nerve (LFCN) is in the area of this approach. Placing the incision as described before, protects the nerve. In the area of the incision, vessels perforating the iliotibial band can be found and need to be cauterized. (Figs. 3a, 3b)

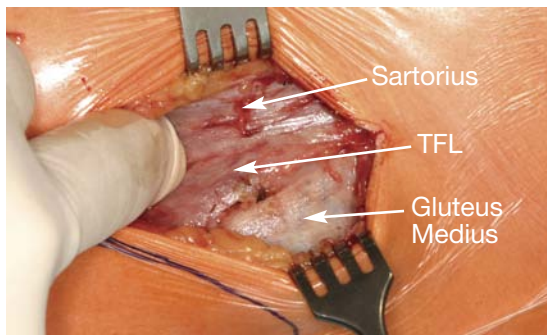


**Figure 3a**



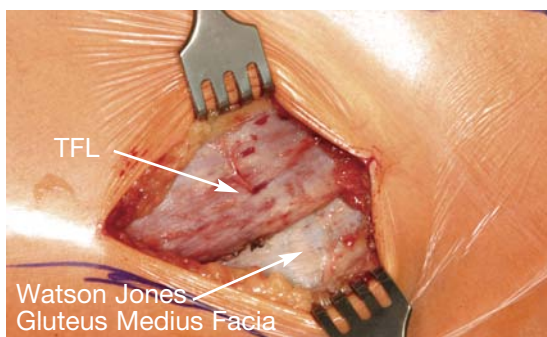
**Figure 3b**

Avoid cutting into the tensor fasciae latae (TFL) before precisely locating the correct portal. Use your index finger in proximal distal movements to palpate the interval between the TFL and sartorius. (Fig. 4)



**Figure 4**

An alternative technique is to identify the fascia of the gluteus medius muscle. This consistently has a whiter more fascial appearance. The muscle immediately medial to this is the tensor fascia. (Fig. 5)



**Figure 5**

## Exposure of the Joint - Lateral Retractors

Sharply incise the fascia of the tensor at its midpoint (medial to lateral). (Fig. 6)

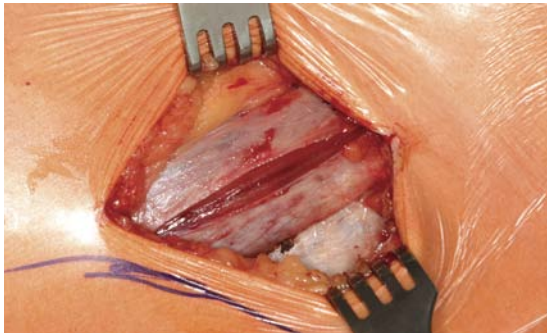


Figure 6

Dissect the fascia from the muscular fibres and perform the next steps strictly under the fascia. Gently pulling the TFL muscle fibers laterally beneath the TFL fascia easily reveals the Smith-Petersen interval – this is identified as a fatty layer. (Fig. 7)

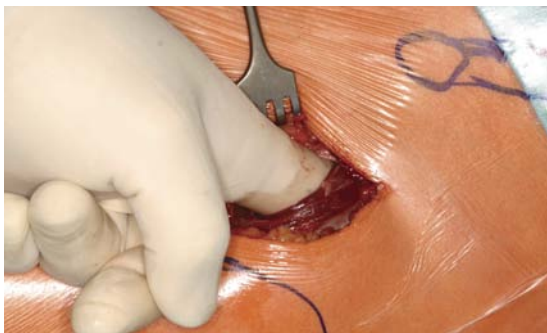


Figure 7

Place the first sharp Narrow Hohmann retractor (1) around the lateral or superior neck. Gentle pushing with your finger in this area prior to placing the retractor can identify the proper retractor location. (Fig. 8)

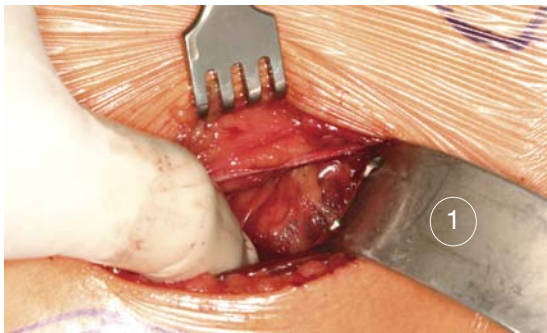


Figure 8

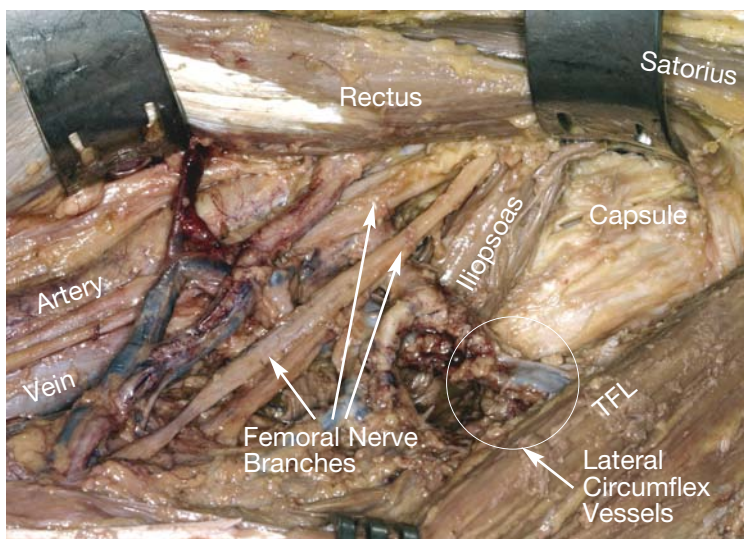
Place the second sharp Narrow Hohmann retractor (2) in the area of the greater trochanter. A rake or Hibbs retractor holds back the medial soft-tissue. (Fig. 9)

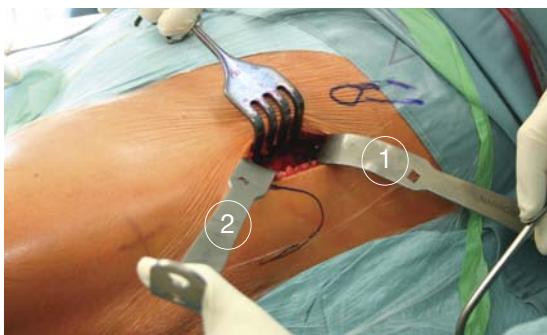

Figure 9

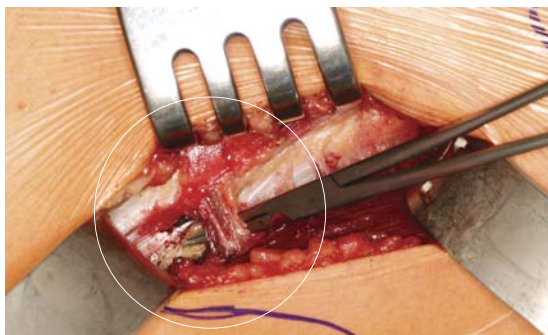


The anatomic situs shows the proximity of vascular structures and the ascending branches of the lateral circumflex vessels which have to be cauterized. (Fig. 10)

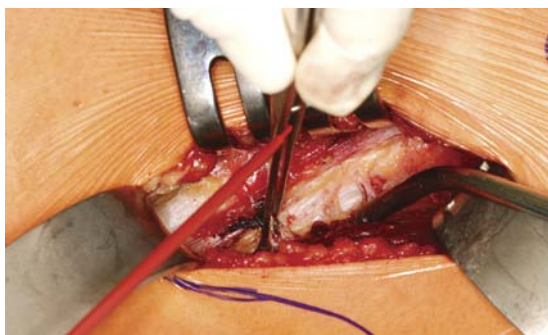

**Figure 10**

The ascending branches of the lateral circumflex vessels need to be identified and cauterized, sutured or clipped. These branches are variable in number. (Fig. 11)



**Figure 11a**



**Figure 11b**

## Exposure of the Joint - Medial & Cranial Retractors

Once cauterized, the surgeon can incise a fascial layer between the rectus and the TFL. This reveals the lateral vastus muscle. The fascia between rectus and capsule is cut with the Colorado Needle or Bovie until the precapsular fat pad is visible. (Fig. 12)

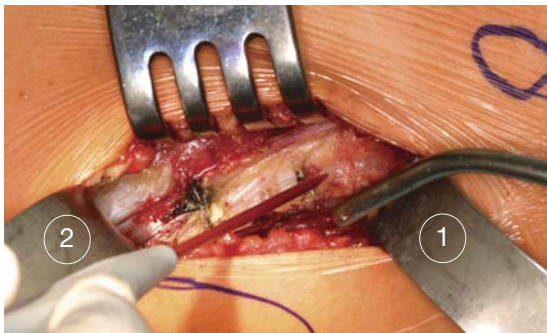

Figure 12

The hip is flexed during this step. A “soft-spot” which offers very little resistance can be palpated just proximal to the lateral vastus muscle. Blunt dissection with a finger or Cobb can identify the proper location for the retractor. (Fig. 13)

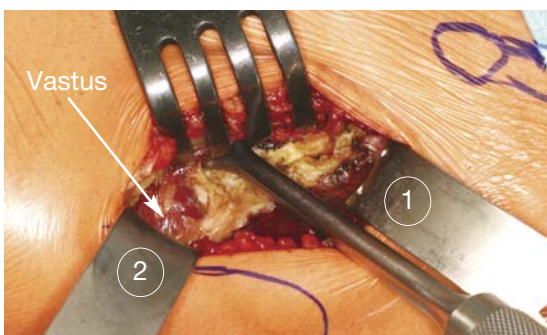

Figure 13a

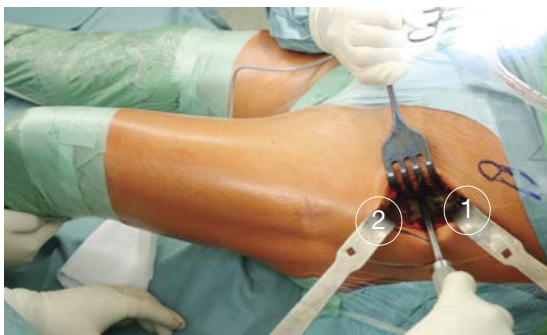

Figure 13b

Place another retractor (3) medial to the neck, thus retracting rectus and sartorius. This can be either a sharp Narrow Hohmann or blunt Narrow Cobra retractor. (Fig. 14)

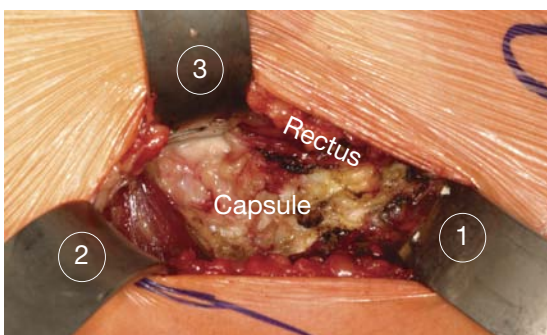
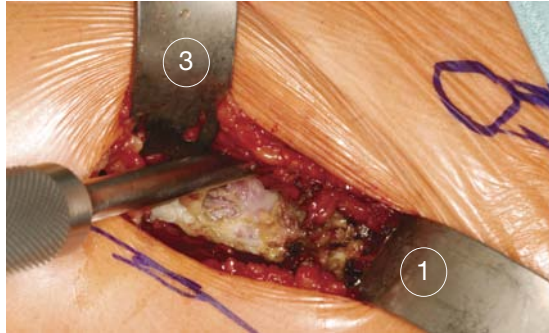
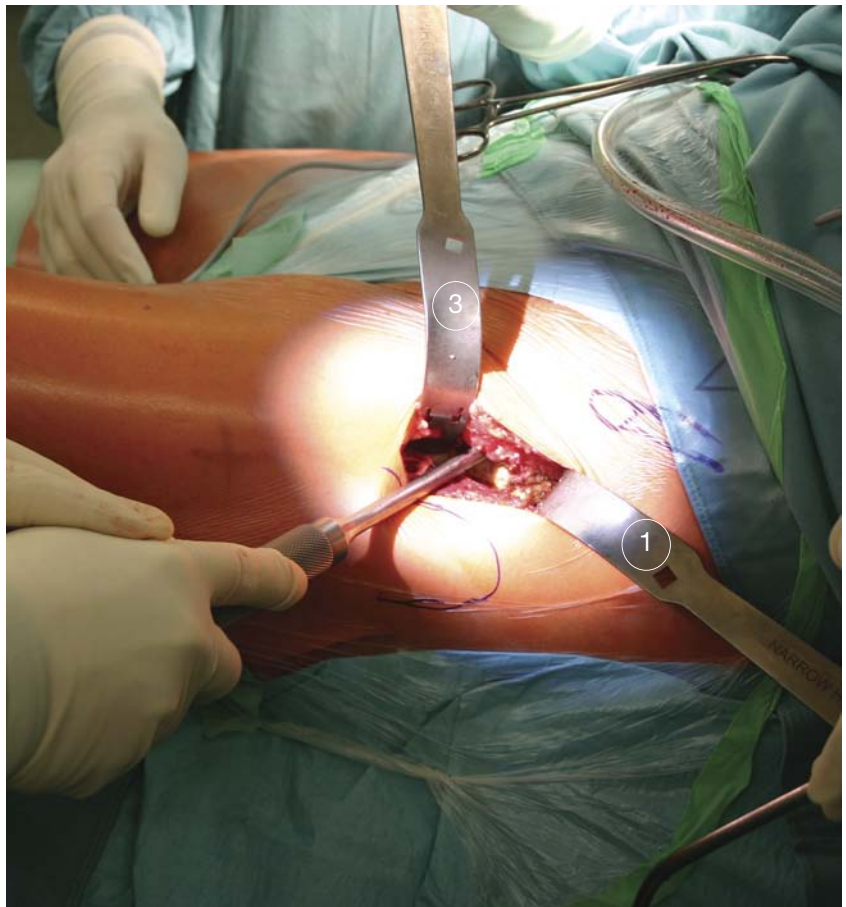


Figure 14

The distal lateral retractor (2) can be removed for this step. After releasing the strong fascia under the rectus the Cobb is used to prepare the space around the ventral rim of the acetabulum. The hip is flexed during this step. (Figs. 15a, 15b)



**Figure 15a**



**Figure 15b**

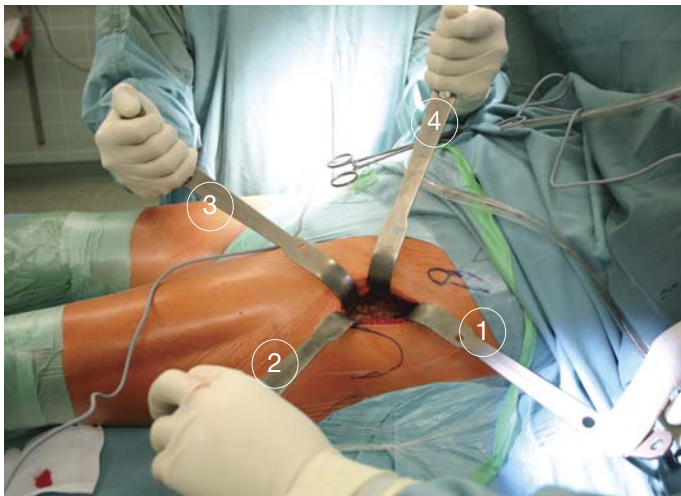


A fourth sharp Narrow Hohmann retractor (4) is placed around the ventral rim. A Light Pipe light attachment to this retractor can enhance dramatically visualization of the acetabulum. If necessary a further release of the rectus fascia can be performed. The lateral distal retractor is put back at its primary position afterwards. (Fig. 16)

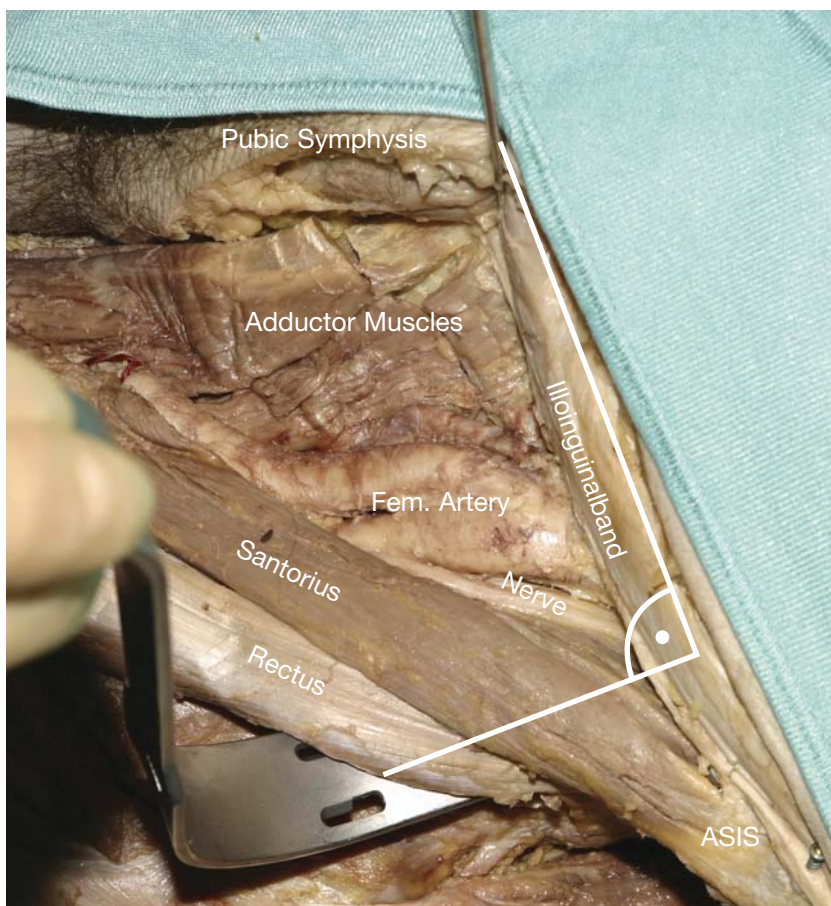


**Light Pipe**

If the retractor is placed perpendicular to the ilioinguinal band and kept under the ilipsoas muscle, injuries of the femoral nerve or the vascular bundle can be avoided. (Fig. 16b)



**Figure 16**



**Figure 16b**



## Preparation of the Capsule

If necessary the reflected head of the rectus can be incised at its capsular insertion. This is only necessary in rare cases. (Figs. 18a, 18b)

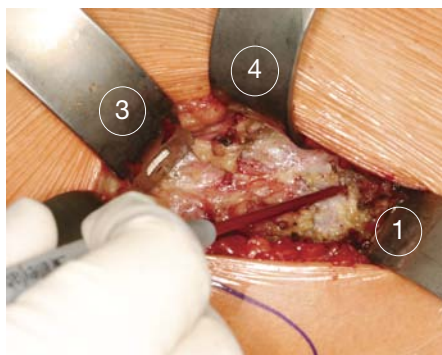


Figure 18a

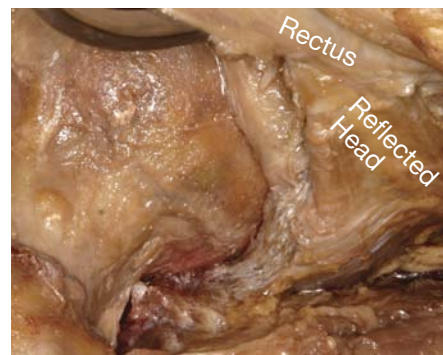


Figure 18b

A non-anatomic description divides the capsule in a ventral, lateral, dorsal and medial portion. In Figure 19 acetabular and corresponding femoral attachments of these capsular parts are shown. Depending on the stiffness of the capsule and experience of the surgeon several variations of capsulotomies and capsulectomies can be performed. All variations have in common a careful detachment of capsular parts from the femoral neck. If it is intended not to perform a total capsulectomy, we recommend a stepwise capsulotomy from 11 o'clock to 6 o'clock. Initially start a partial capsulectomy from 11 o'clock to 3 o'clock. The flap from 3 o'clock is detached from the acetabulum as far as possible but not resected. Place the medial retractor (3) medial to the neck inside the capsule. (Figs. 19, 20)

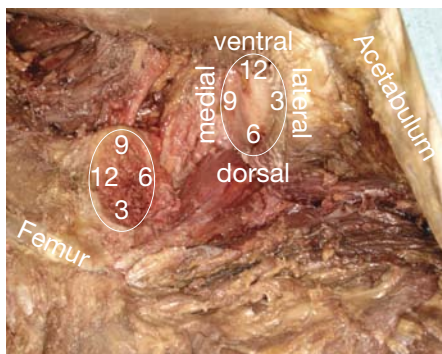


Figure 19

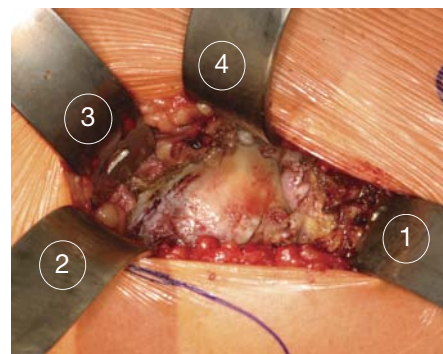


Figure 20

Carefully clear the “saddle” between greater trochanter and the neck as this serves as starting point for the neck osteotomy. (Figs. 21a, 21b)

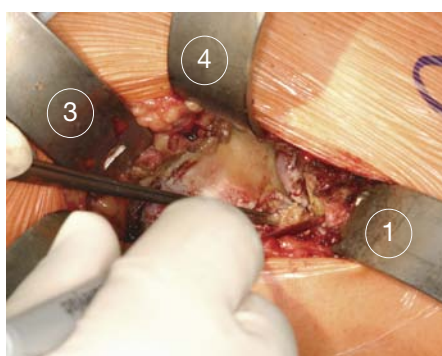


Figure 21a

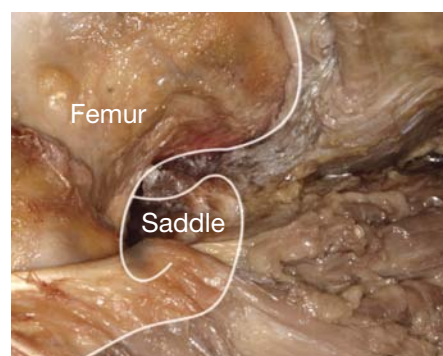


Figure 21b



## In Situ Osteotomy and Removal of the Femoral Head

Remove the supero-lateral retractor (1) and place a Blunt Narrow Cobra retractor (5) intracapsularly in order to protect the tip of the greater trochanter during the osteotomy. (Fig. 22)

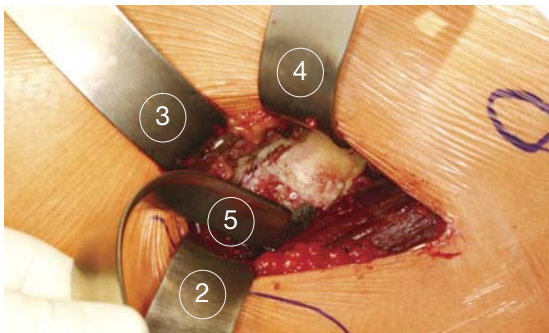


Figure 22

Perform the definitive osteotomy with a Stryker CORE Micro Saw or a standard power tool with a long and small saw-blade.

The proximal osteotomy should be as proximal as possible. Make sure that both osteotomies are parallel. If a wedge is created, removal of the neck might be difficult.

The use of longer saw blades increases the risk of cuts into the acetabulum or the tip of the greater trochanter. (Fig. 23)

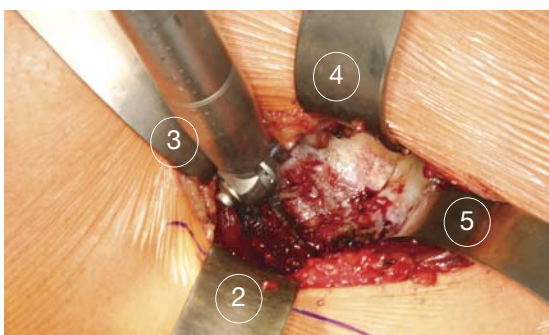


Figure 23

Make sure that the first osteotomy is complete and perform the second osteotomy on a line from the saddle of the neck approximately 1 cm distal to the first osteotomy. (Fig. 24)

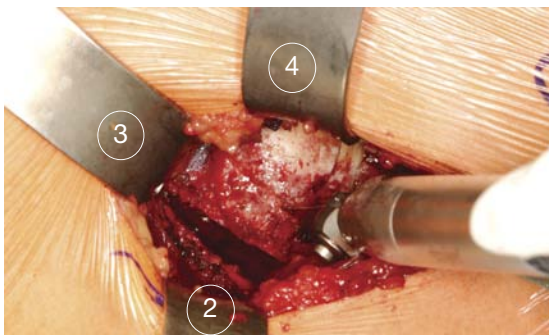


Figure 24

Use the Cobb or a chisel to mobilize the neck disk. (Fig. 25)

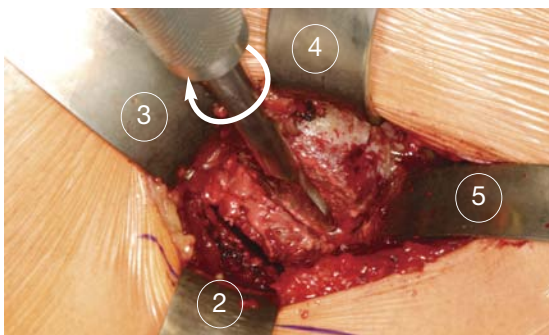
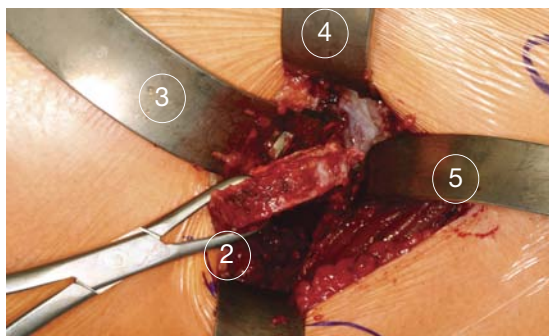


Figure 25

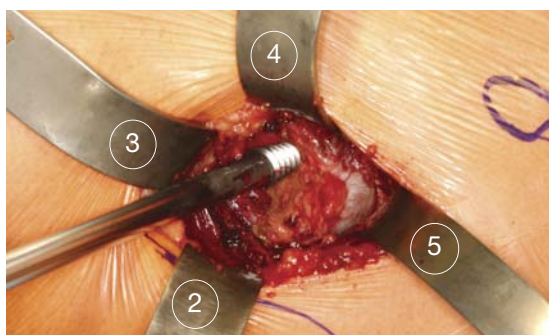


Remove the neck disk with a clamp or tenaculum. Gentle traction on the leg will facilitate this step. (Fig. 26a)

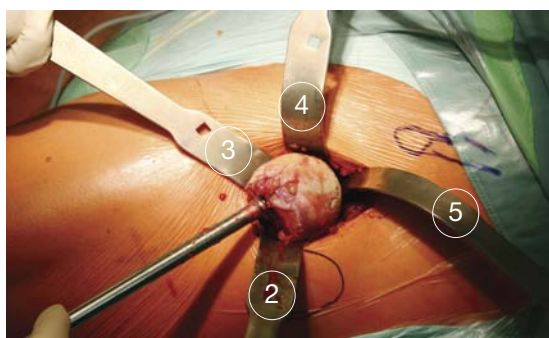


**Figure 26a**

A Femoral Head Extractor corkscrew is used to remove the remaining head. A gentle but constant longitudinal pull is the best technique for removal of the head. Anterior acetabular osteophytes may need to be removed first in order to facilitate femoral head removal. (Figs. 26a, 26b)

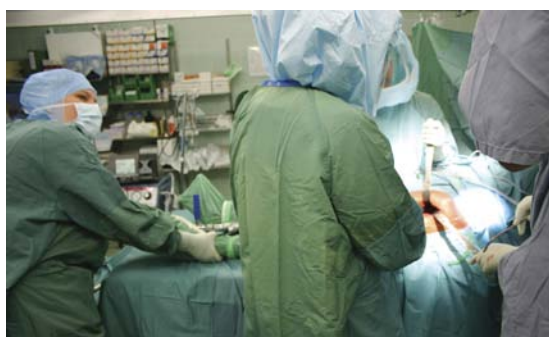

**Figure 26b**



**Figure 26c**

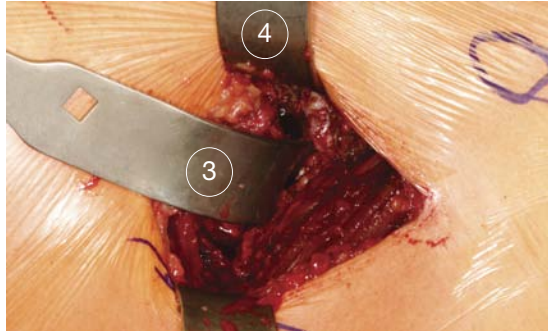
These steps can be ameliorated by pulling the leg. (Fig. 27)



**Figure 27**

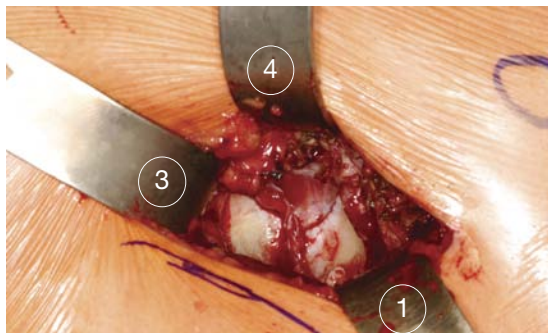## Acetabular Exposure

The ventral retractor (4) is kept in place. Remove all other retractors from their position. A sharp Narrow Hohmann retractor (3) is positioned in the middle of the acetabulum and orientated medially. Scratch along the bone until soft tissue is reached. Now place this retractor around the transverse ligament. (Fig. 28)



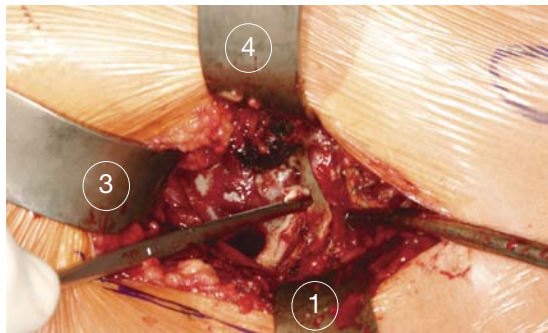
**Figure 28**

A sharp Narrow Hohmann retractor is placed lateral to the acetabulum (1). Occasionally, it is necessary make a small nick in the capsule to facilitate placement of this retractor. (Fig. 29)



**Figure 29**

Remove the remaining parts of the labrum. (Fig. 30)

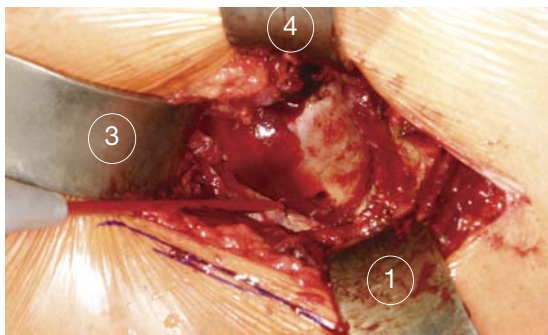


**Figure 30**



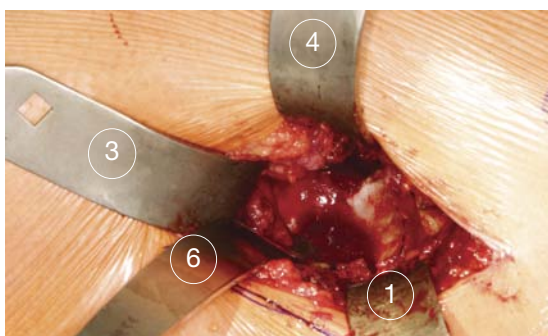## Preparation of the Acetabulum Method 1

Incise the dorsal capsule (it usually forms a roll) in the middle of the acetabulum. This is at 6 o'clock in the middle of the dorsal portion of the capsule. (Fig. 31)



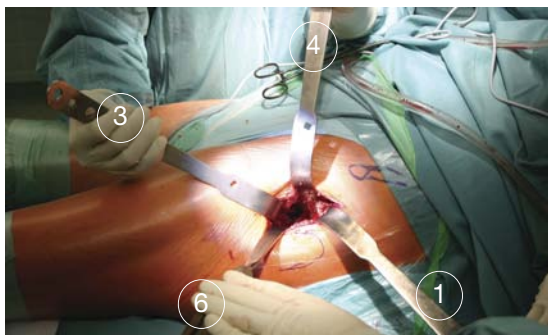
**Figure 31**

Place a double pronged BG Femoral Elevator (6) at the dorsal rim of the acetabulum. (Fig. 32)



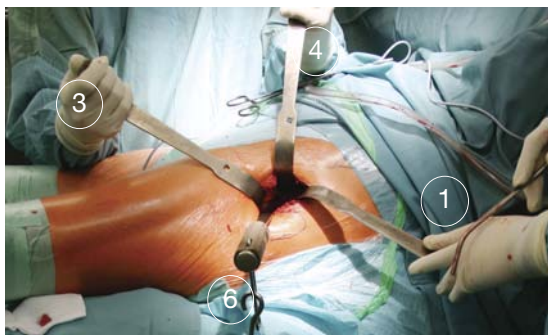
**Figure 32**

The retractor can either be held by the first assistant or weights can be used. (Fig. 33a)



**Figure 33a**

Ream to the correct size using the Offset Reamer Handle. (Fig. 33b)



**Figure 33b**



## Preparation of the Acetabulum Method 2

Place the first reamer in the acetabulum. (Fig. 35)

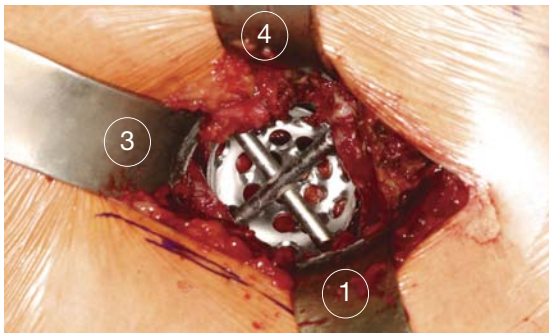


Figure 35

Introduce the Offset Reamer Handle and connect it to the reamer. (Fig. 36)

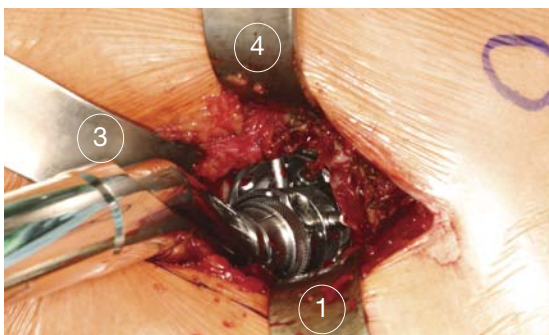

Figure 36

After reaming, the first assistant uses a clamp to open the locking mechanism of the reamer. The Offset Reamer Handle is disconnected and removed. Remove the reamer with a Kocher clamp. (Figs. 37a, 37b)

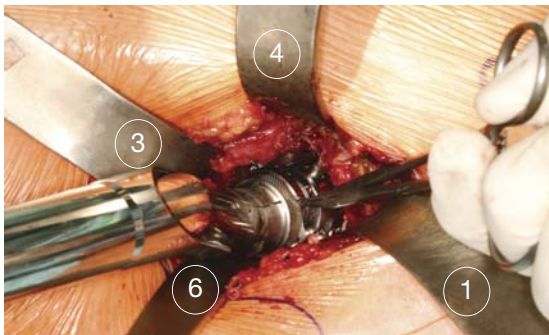


Figure 37a

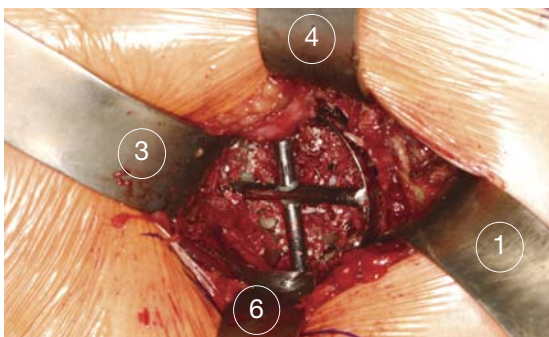
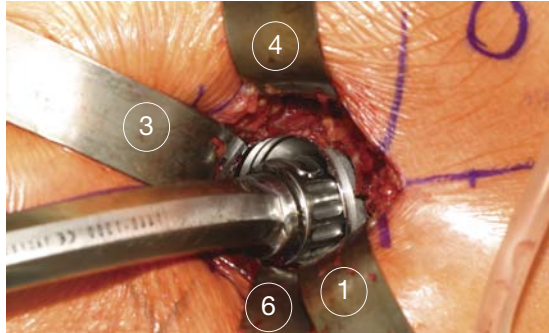


Figure 37b

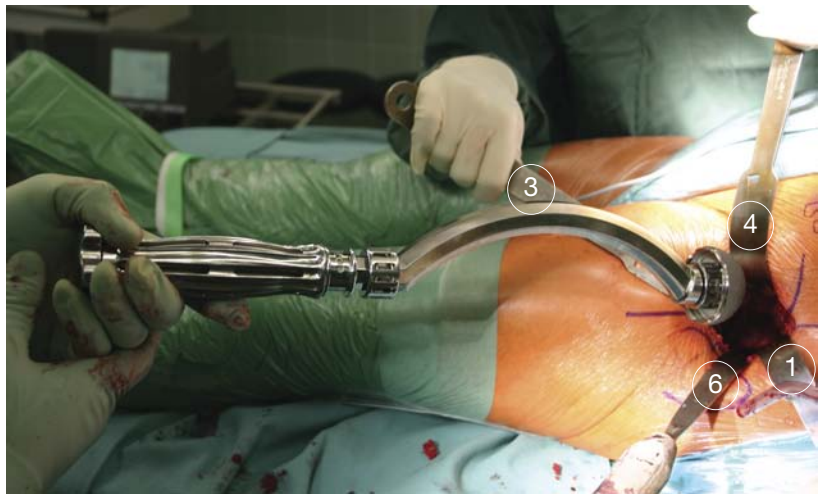

## Cup Impaction

After trialing, use the Curved Positioner Impactor to impact the final cup.  
(Figs. 38a, 38b)

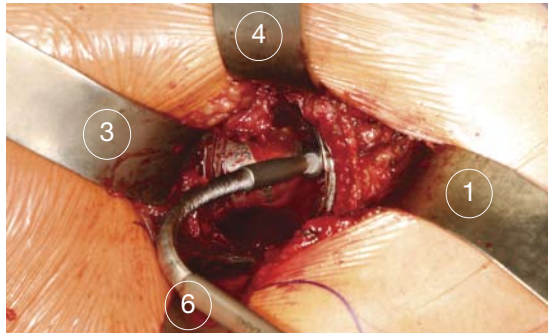


**Figure 38a**

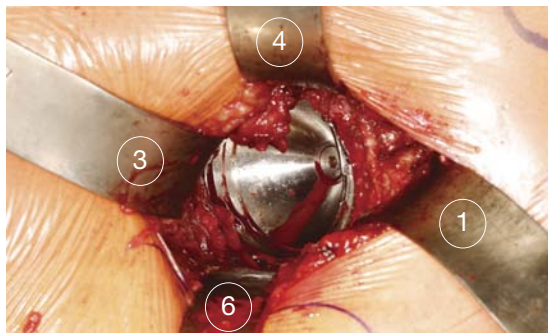

**Figure 38b**

If screws are placed or the locking screw is inserted, use a flexible screw driver.  
(Figs. 39a, 39b)



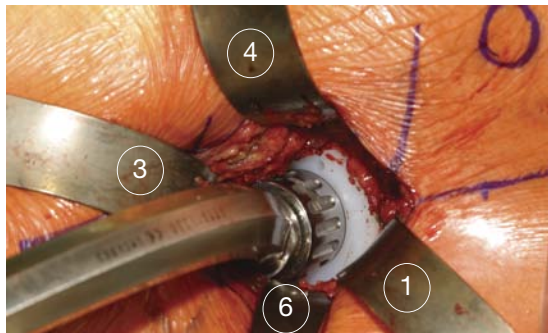
**Figure 39a**



**Figure 39b**

Insert the liner.

At this point, femoral preparation will occur. Remove retractors (1 + 6) and leave the anterior (lighted) retractor (4) and optionally the medial retractor (3). Leaving these retractors in place will facilitate exposure of the femur. (Fig. 40)



**Figure 40**

## Preparation of the Dorsolateral Capsule

Put a sharp Narrow Hohmann retractor (1) to the lateral aspect of the greater trochanter. Put the BG Femoral Elevator (7) between capsule and external rotator. The lateral capsular flap is grasped with a clamp. Use the Colorado Needle to dissect the fat-tissue layer between the capsule and the dorsal group of muscles (piriformis, obturator, gemelli). (Fig. 41a)

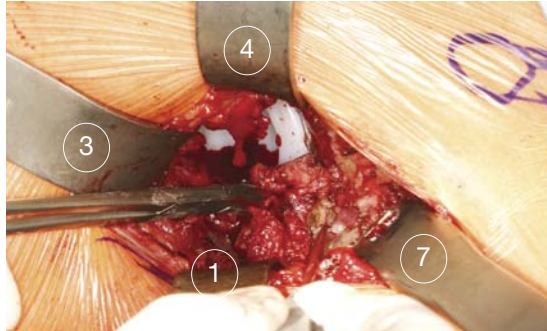


Figure 41a

In order to ameliorate this step, place the leg in adduction and external rotation. The resection of this capsular flap to incision in the dorsal capsule finalizes the partial capsulectomy from 11 o'clock to 6 o'clock leaving the capsule from 6 o'clock to 11 o'clock in place (see Figure 19). (Fig. 41b)

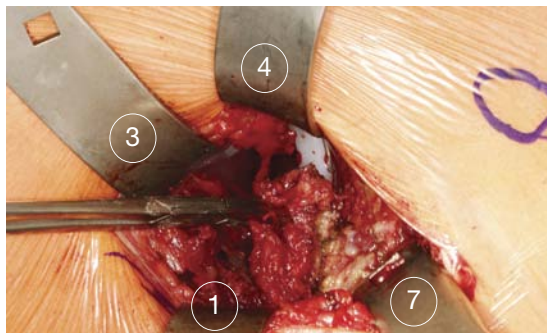


Figure 41b

After removal of the dorso-lateral capsule, the short external rotators can be seen. (Fig. 42)

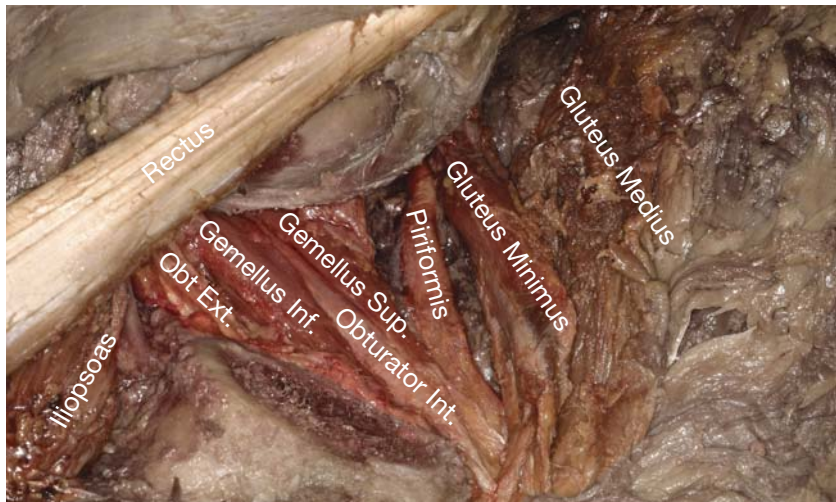


Figure 42



## Figure 4 Position to Mark Femoral Orientation (optional)

Bring the leg in a “Figure 4” position and place one retractor medial and one lateral to the femur, thus presenting the calcar which is still covered with capsular tissue. (Fig. 43a)

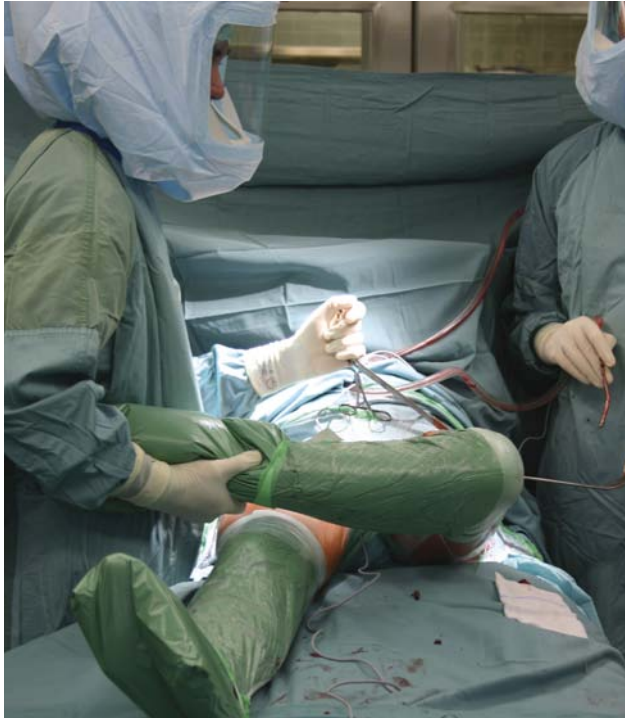

Figure 43a

Use two sharp Narrow Hohmann retractors to expose the calcar. Remove the capsular tissue. (Fig. 43b)

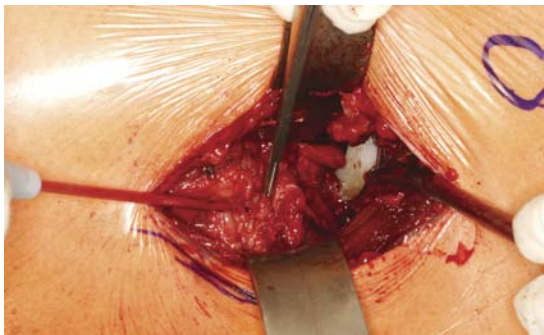


Figure 43b

Mark the neutral rotation of the femur with the cautery. (Fig. 44)

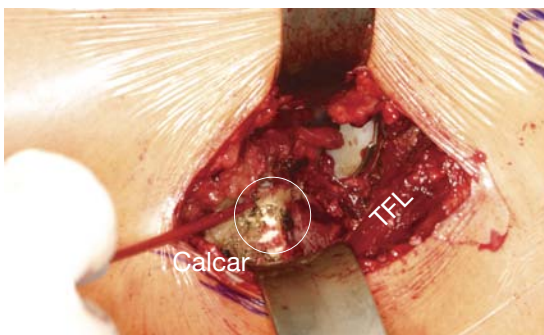


Figure 44

## Exposure of the Femur

Break the leg part of the table by about 30° - 40°. (Figs. 45, 46)

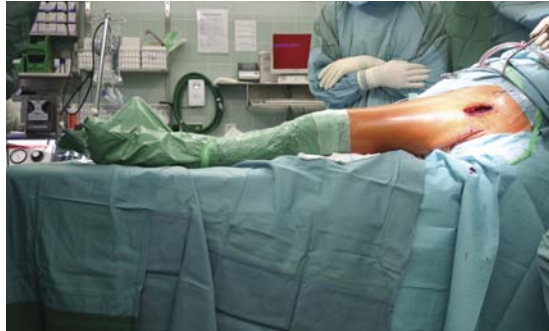

Figure 45

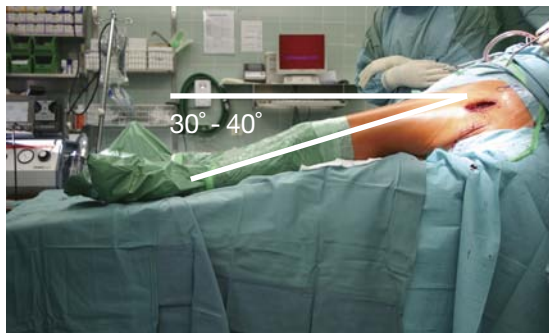

Figure 46

A double pronged BG Femoral Elevator retractor (8) is placed behind the greater trochanter but in front of the gluteus medius muscle. A Bone Hook (9) is then placed into the calcar area of the femoral neck. A gradual but firm anterior pull will elevate the femur. The double pronged BG Elevator is then positioned to hold the femur in its elevated position. Additional releases of the posterior structure may be required to achieve proper femoral exposure.

In some cases the tip of the greater trochanter is placed behind the acetabulum. Therefore, pull the Bone Hook first laterally in order to free the greater trochanter and then pull anteriorly.

Always combine pulling the hook and levering with the BG Femoral Elevator in order to minimize the forces to the greater trochanter. (Figs. 47a, 47b)

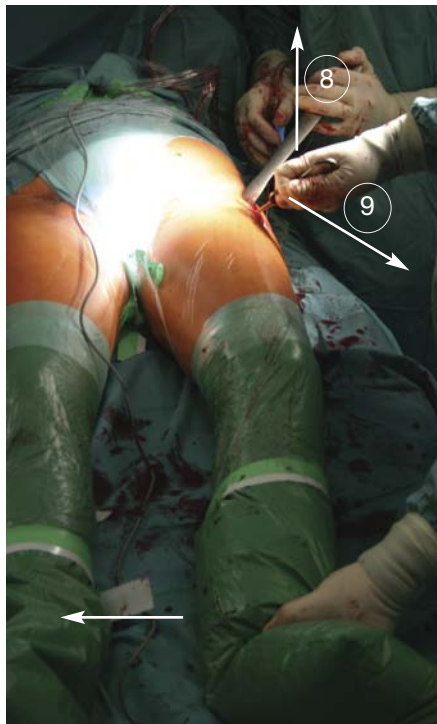


Figure 47a

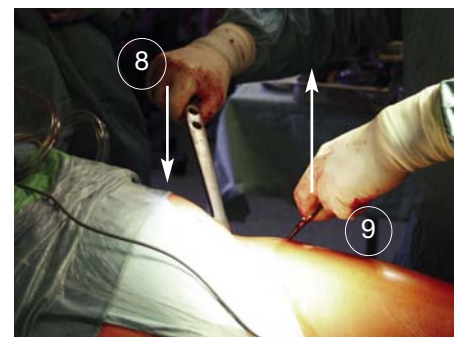
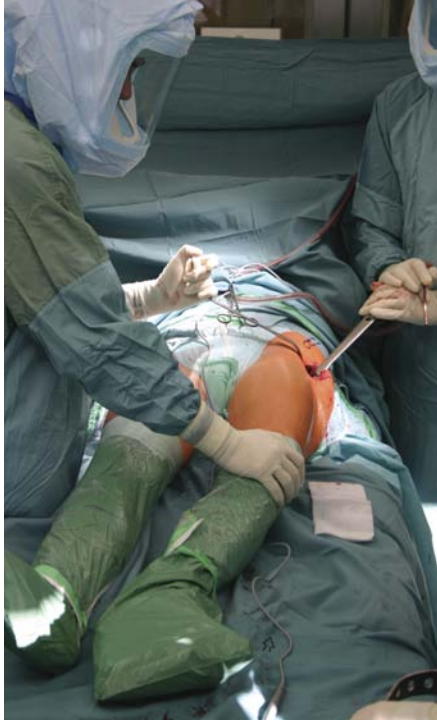
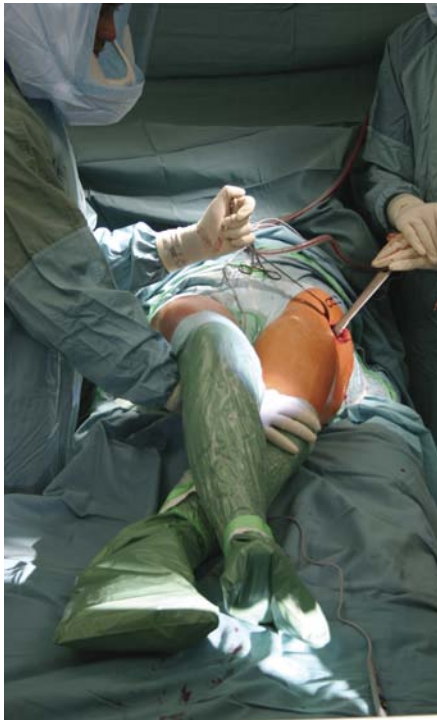Figure 47b



The opposite leg is hyper-abducted and the second assistant externally rotates the leg at the knee. Alternatively, the opposite leg can be crossed over the operated leg and the assistant's hand in order to support external rotation. The operated leg must be placed with a straight knee in order to reduce muscular force at the proximal femur and to optimize the exposure of the proximal femur. (Figs. 48a, 48b)



**Figure 48a**



**Figure 48b**

## Possible Releases

At the tip of the greater trochanter and in the trochanteric fossa, the attachments of gluteus minimus, piriformis, gemellus superior, internal obturator and gemellus inferior can be found. (Fig. 49)

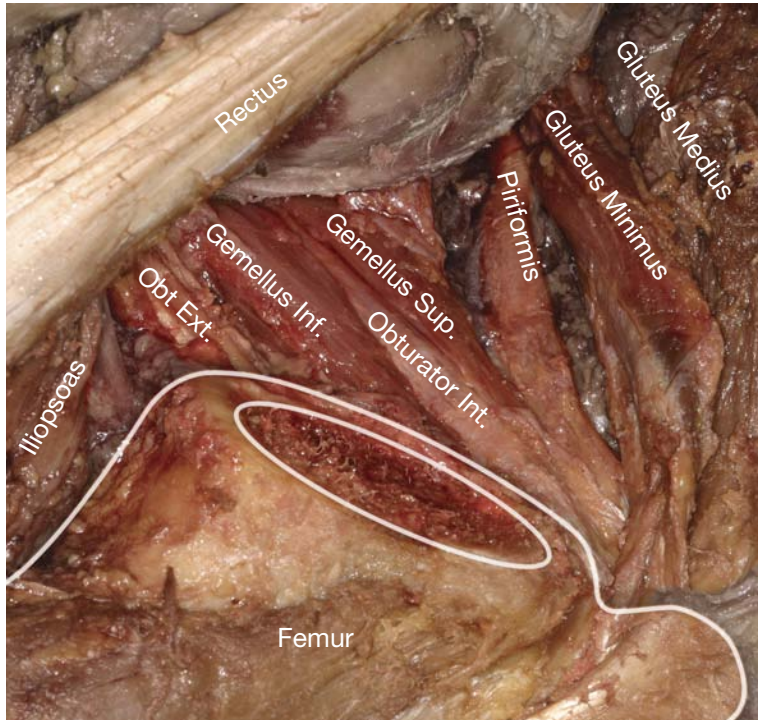


Figure 49

A sharp Narrow Hohmann retractor (11) is placed at the calcar area proximal to the iliopsoas tendon. Additionally another sharp Narrow Hohmann retractor can be placed laterally at the proximal femur in order to pull back the lateral soft tissue. After exposing the femur, releases of the above mentioned tendons can be performed, if necessary. (Figs. 50a, 50b)

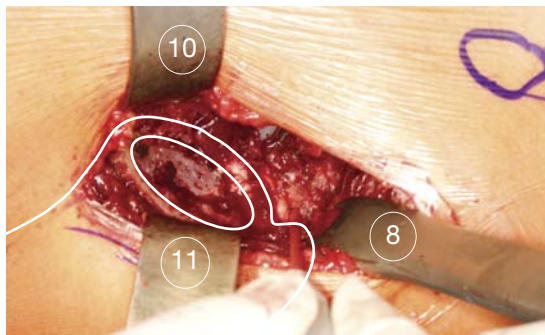


Figure 50a

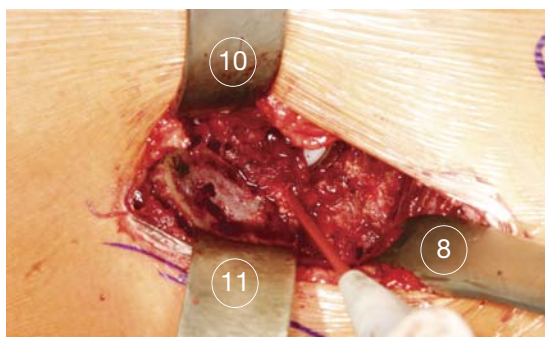
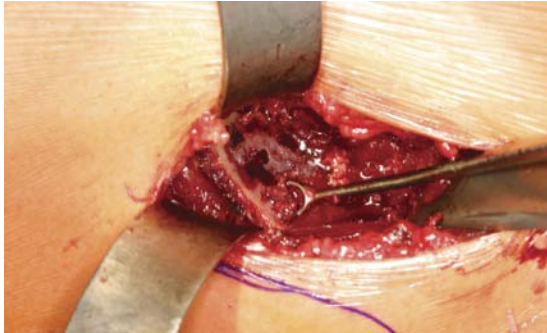


Figure 50b

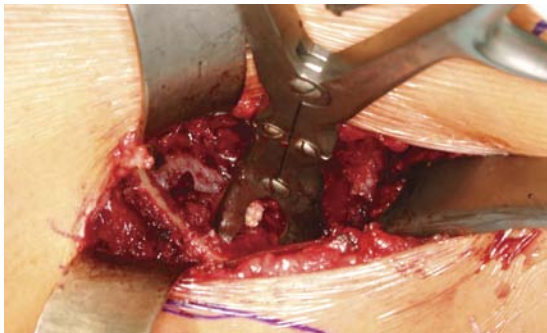
## Opening the Femoral Canal

An angulated Curette is used to carefully open and probe the direction of the femoral canal. (Fig. 51)



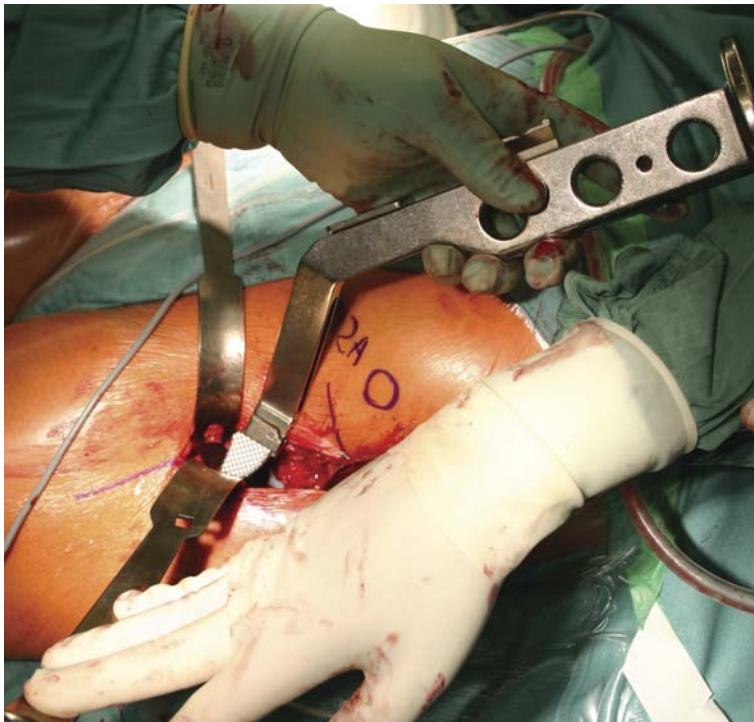
**Figure 51**

A Rongeur can be used to extend the opening in the direction of the greater trochanter. (Fig. 52)



**Figure 52**

A proximal Accolade TMZF Starter Rasp is used to form the proximal canal. (Fig. 53)

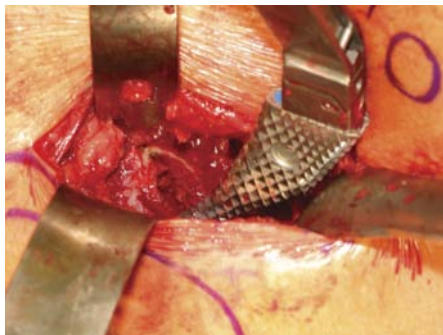


**Figure 53**

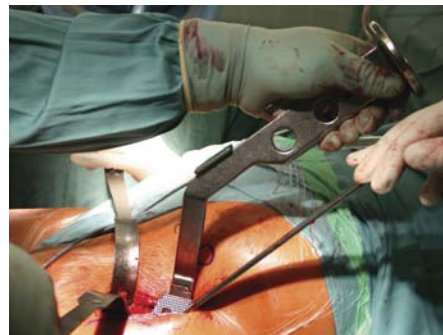

## Rasping the Femur

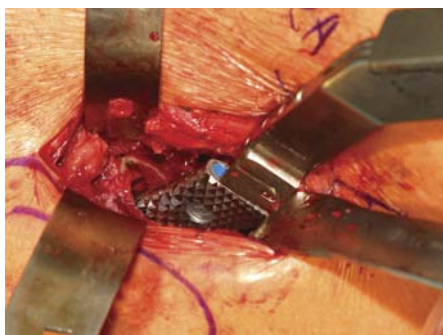
Next, insert the Accolade TMZF Rasp size 0 without significant force into the canal until the rasp is aligned with the femur. Once there is full introduction of the rasp, hammering can then begin. (Figs. 54a–54g)



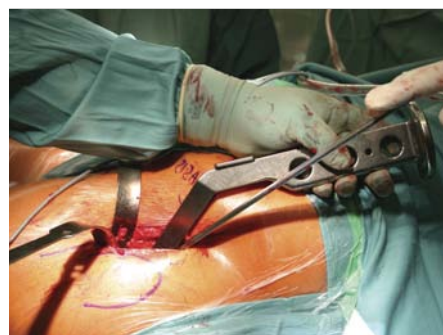**Figure 54a**



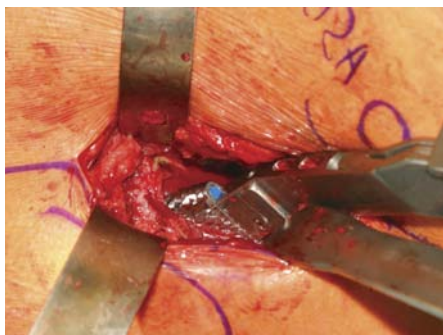
**Figure 54b**



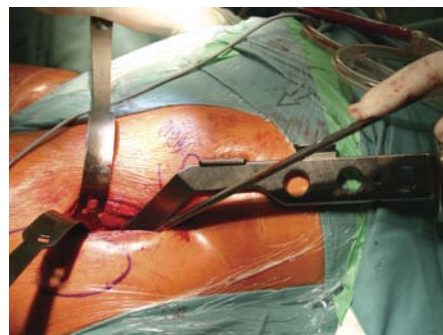
**Figure 54c**



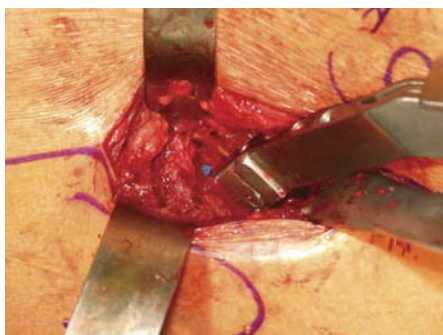
**Figure 54d**



**Figure 54e**

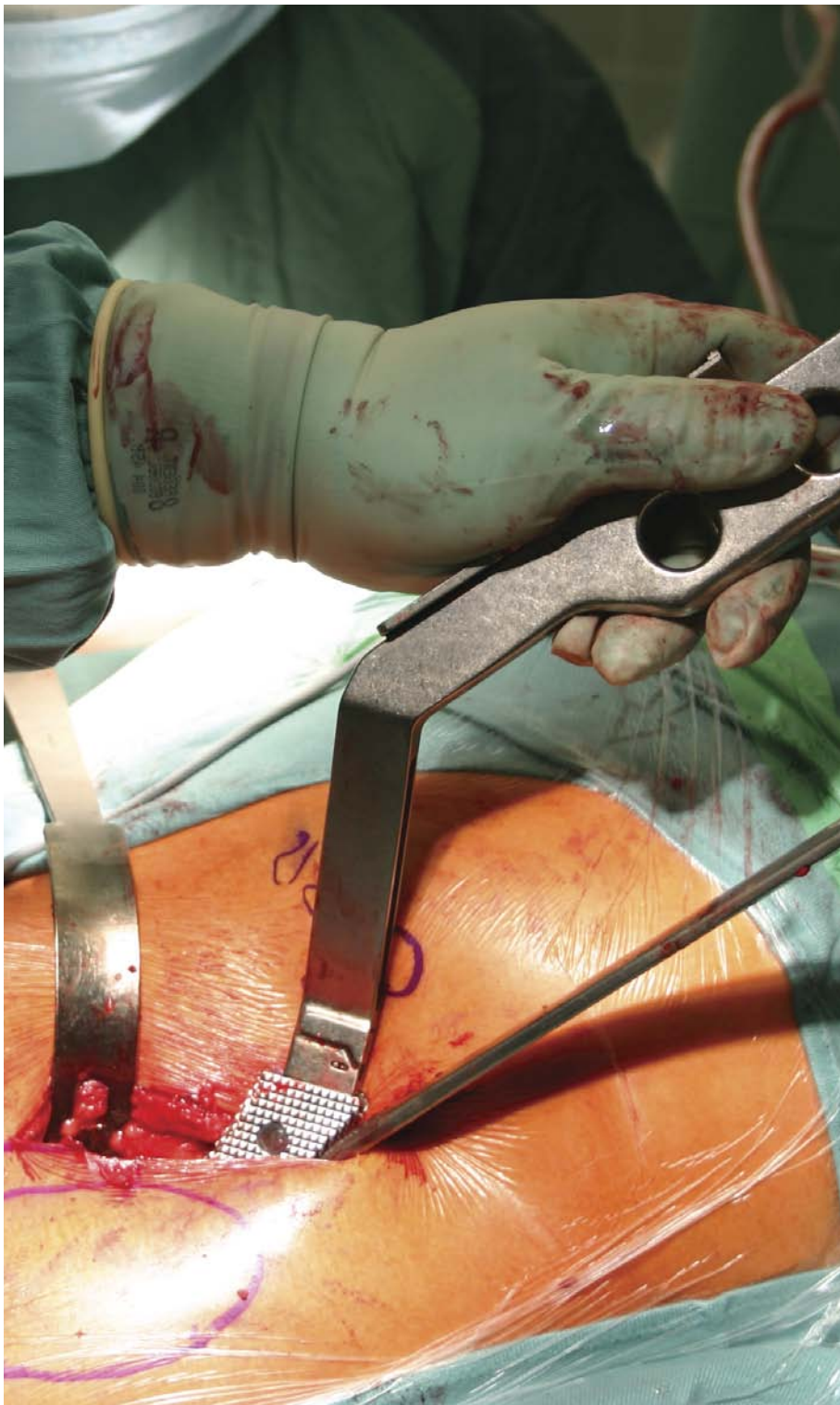

**Figure 54f**



**Figure 54g**

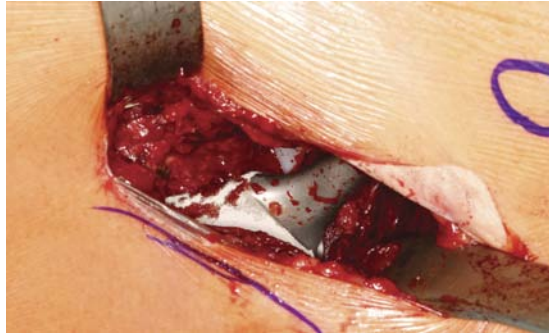The Dual Offset Accolade Rasp Handle can facilitate the introduction and alignment of the broaches and offers the additional advantage of reducing the exposure needed of the proximal femur.





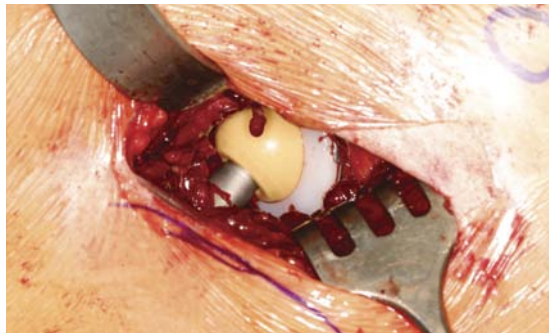
## Implantation and Closure

The final implant is introduced by hand and then impacted gently into the canal. A straight bullet nosed Accolade TMZF Stem Impactor can be used to impact the femoral stem at a 30 - 45 degree angle in the standard fashion. This insures lateralization of the femoral component and minimizes the chance of a medial calcar fracture. (Fig. 56)



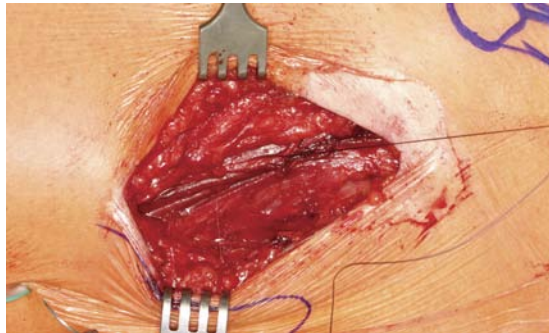
**Figure 56**

The final head is attached. (Fig. 57)



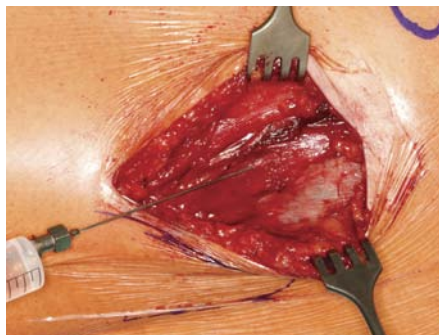
**Figure 57**

The muscular fascia is sutured. Care is taken to avoid placing sutures too far medially (remember the LFC nerve is there). (Fig. 58)

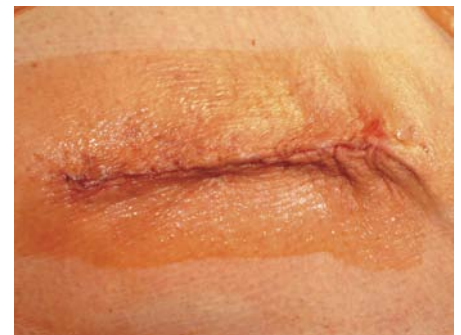

**Figure 58**

Local anaesthetics can be injected regionally, based on surgeon preference. (Figs. 59, 60)



**Figure 59**



**Figure 60**

---

## Stryker MIS Instrumentation

NAV Compatible Dual-Offset Accolade Rasp Handle  
(Left & Right)



Curved Positioner/Impactor



Offset Reamer Handle




Blundt Narrow Cobra Retractor  
Narrow Hohmann Retractor



BG Femoral Elevator



Accolade TMZF Starter Rasp



Universal Accolade TMZF  
Stem Impactor



Light Pipe



**Direct Anterior Set Contents**

2124-1700	Right - Nav Compatible Dual-Offset Accolade Rasp Handle
2124-1750	Left - Nav Compatible Dual-Offset Accolade Rasp Handle
2124-1899	Universal Accolade TMZF Stem Impactor
4200-130-0	Accolade TMZF Starter Rasp
48498005	(2) BG Femoral Elevators
1440-1130S	(3) Narrow Hohmann Retractors
1440-1140	(2) Blunt Narrow Cobra Retractors
4200-105-0	Direct Anterior THA Case/Tray

**Acetabular Instruments**

T6320	Offset Reamer Handle
<b>Curved Positioner/Impactor</b>	
1440-0030	MIS Acetabular Instruments - General Tray
1440-1300	Curved Positioner/Impactor
1440-1370	Lateral Decubitus Alignment Guide
1440-1380	Supine Alignment Guide
1440-1310	Trident Cup Tip
1440-1320	ABG Cup Tip
1440-1328	28mm Poly Insert Tip
1440-1332	32mm Poly Insert Tip
1440-1336	36mm Poly Insert Tip
1440-1328D	28D Ceramic Insert Tip
1440-1332E	32E Ceramic Insert Tip
1440-1332F	32F Ceramic Insert Tip
1440-1336G	36G Ceramic Insert Tip
1440-1336H	36H Ceramic Insert Tip
1440-1336I	36I Ceramic Insert Tip
2112-0000	Ceramic Insert Removal Tool
1440-1350	U-Joint Flexible Shaft - Positioner/Impactor

**Femoral Instruments**

5900-0050	T-Handle
1440-1010	Femoral Head Extractor
1440-1070	Head Impactor
1440-1040	Quick Connect Handle
1440-1700	Neck Trial Forceps
1440-0001	Single High Case
1440-0002	Double High Case
1440-1080	Light Pipe



**Notes:**

**Notes:**









---

**Joint Replacements**

---

**Trauma, Extremities & Deformities**

---

**Craniomaxillofacial**

---

**Spine**

---

**Biologics**

---

**Surgical Products**

---

**Neuro & ENT**

---

**Interventional Spine**

---

**Navigation**

---

**Endoscopy**

---

**Communications**

---

**Imaging**

---

**Patient Care & Handling Equipment**

---

**EMS Equipment**

---

325 Corporate Drive  
Mahwah, NJ 07430  
t: 201 831 5000

[www.stryker.com](http://www.stryker.com)

A surgeon must always rely on his or her own professional clinical judgment when deciding whether to use a particular product when treating a particular patient. Stryker does not dispense medical advice and recommends that surgeons be trained in the use of any particular product before using it in surgery.

The information presented is intended to demonstrate the breadth of Stryker product offerings. A surgeon must always refer to the package insert, product label and/or instructions for use before using any Stryker product. Products may not be available in all markets because product availability is subject to the regulatory and/or medical practices in individual markets. Please contact your Stryker representative if you have questions about the availability of Stryker products in your area.

Stryker Corporation or its divisions or other corporate affiliated entities own, use or have applied for the following trademarks or service marks: Accolade, Stryker, TMZF, Trident. All other trademarks are trademarks of their respective owners or holders.

Literature Number: **LMISH-AST Rev. 2**  
MS/GS 05/11

Copyright © 2011 Stryker  
Printed in USA

